

6-1-2018

Blood group chimerism is not rare anymore

Mohandoss Murugesan

Department of Transfusion Medicine Malabar Cancer Centre, Thalassery, drmohandossm@gmail.com

Vinu Rajendran

Department of Transfusion Medicine Sree Chitra Tirunal Institute for Medical Science and Technology, Trivandrum, drmohandossm@gmail.com

Follow this and additional works at: <https://impressions.manipal.edu/mjms>



Part of the [Medicine and Health Sciences Commons](#)

Recommended Citation

Murugesan, Mohandoss and Rajendran, Vinu (2018) "Blood group chimerism is not rare anymore," *Manipal Journal of Medical Sciences*: Vol. 3 : Iss. 1 , Article 9.

Available at: <https://impressions.manipal.edu/mjms/vol3/iss1/9>

This Case report is brought to you for free and open access by the MAHE Journals at Impressions@MAHE. It has been accepted for inclusion in Manipal Journal of Medical Sciences by an authorized editor of Impressions@MAHE. For more information, please contact impressions@manipal.edu.

Case Report

Blood group chimerism is not rare anymore

Mohandoss Murugesan*, Vinu Rajendran

Email: drmohandoss@gmail.com

Abstract

ABO discrepancies due to mixed-field agglutination are commonly seen with subgroups of A or B and ABO-incompatible RBC transfusion in routine immunohematology laboratory. We report a 20 year old male with minor ABO and Rh D mismatched hematopoietic stem cell transplantation presenting with blood group chimerism. Column agglutination technique (CAT) had advantages in detecting mixed field agglutination than other techniques used in routine blood grouping.

Key words: Chimerism, blood group, mixed field, column agglutination technique, SPRCA

Introduction

Chimerism is commonly referred as presence of two genetically distinct populations within an individual. Blood group chimerism is a usually rare phenomenon which can be either congenital or acquired. The common causes for acquired chimerism are ABO incompatible blood transfusion, allogenic stem cells and solid organ transplantation. They are usually recognized at the time of blood grouping in form of ABO discrepancies in forward group typing with the presence of mixed-field red blood cell (RBC) agglutination or discrepancies between forward and reverse typing.¹

Figure 1A: Patient Blood Group with Type II discrepancy

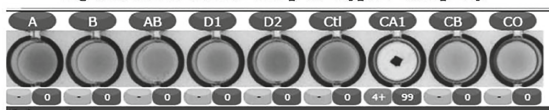
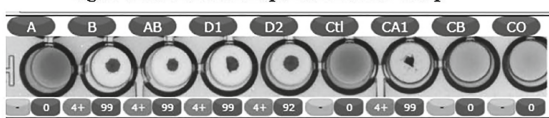


Figure 1B: Patient Pretransplantation Blood Group



Mohandoss Murugesan

Department of Transfusion Medicine
Malabar Cancer Centre, Thalassery

Vinu Rajendran

Department of Transfusion Medicine
Sree Chitra Tirunal Institute for Medical Science and Technology,
Trivandrum

*Corresponding Author

Manuscript received : 21/11/17

Revision accepted : 11/12/17

Case Report

A 20-year-old male blood sample was received for blood grouping without clinical details. Blood grouping was performed using the electromagnetic technology (Qwalys, Diagast) in a solid phase red cell adherence assay (SPRCA) platform. The forward grouping had no reactions with any type of antibodies and the reverse grouping showed clumps in A₁ cells (Figure 1). Initially, type II ABO grouping discrepancy with weak or missing B antigen was suspected.

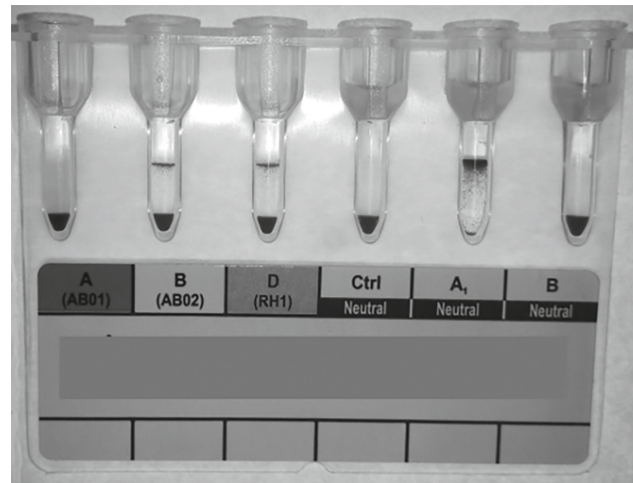


Figure 2: Repeat ABO and Rh D typing in Column Agglutination Technique

The possibility of a technical error was investigated and the test on the group was repeated with tube technique and column agglutination technique (CAT)

How to cite this article: Murugesan M, Rajendran V, Blood group chimerism is not rare anymore. *MJMS*. 2018; 3(1): 50-52.

(Biorad). The repeat tube technique confirmed the presence of type II ABO discrepancy. On incubating the tubes at 4°C for 1 hour, a weak reaction was noticed with Anti B and Anti D confirming B subgroup and Rh D variant phenotype, respectively. However, the CAT assay demonstrated presence of two bands of cells in the Anti B and the Anti D in forward group, suggesting mixed field agglutination requiring detailed investigation (Figure 2).

Mixed-field agglutination in forward grouping is usually noticed in subgroups of A or B and ABO-incompatible RBC transfusion in routine immunohematology laboratory. In this case, the patient’s clinical details were not given initially and found to have prior history of Minor ABO and Rh D mismatched hematopoietic stem cell transplantation three months back. The patient’s historical group was retrieved and was found to be B Rh D Positive (Figure 1) and the stem cell donor group was found to be O Rh D Negative thus, confirming chimerism due to ABO and Rh D incompatible transplantation (Table 1).

Discussion

Blood group chimerism was an underreported entity. With more bone marrow transplantation procedures in the country blood group chimerism due to ABO mismatch transplantation is increasing. Most laboratories perform conventional tube technique for blood grouping. Mixtures of 50/50% or 25/75% cell populations are detected in tube technique; however, a 5/95% minor cell population can be missed in routine blood grouping.² In present case, tube technique at 4°C, macroscopic reading of the reaction with Anti B and Anti D was misinterpreted as weak initially; later confirmed mixed field pattern by microscopy. With newer automated methods in the form of microwell, column agglutination

and solid phase, most centres prefer automation in pretransfusion testing due to increased sensitivity, decreased personnel requirement, and ease of archiving and transferring data.

Many articles have described the advantages of CAT and SPRCA assay over conventional tube technique but very limited articles discuss about mixed field detection using these platforms. Summers et al. compared three automated platforms (Microwell / CAT / SPRCA) for detecting mixed filed agglutination reactions with control samples (100% D+, 90% D+ with 10% D-, 50% D+ with 50% D-, 10% D+ with 90% D-, and 100% D-). SPRCA failed to identify or flag any of the mixed field reactions. With automated microwell technique, mixed field reaction was clearly evident till 50% D+ control and visual suspicion for mixed field was present with 90% D+ and 10% D+ control. Automated CAT reported these mixed field pattern as unclear reactions, and visual inspection of the columns by the user clearly identified the mixed-field reactions.³

CAT has better advantages in detecting mixed-field agglutination patterns as the antibody-coated agglutinated RBCs can be trapped in the matrix near the top while non-agglutinated RBCs will pass through the matrix to the bottom. Thus, clearly discriminating the presence of an acquired population from the inherited ones.

In a study by Greendyke and colleagues, skilled blood bank technologist could detect only 12% of mixed field agglutination patterns by tube technique and only 50% of their staff was able to detect these mixed filed patterns.⁴ Parker et al. in their study reported that greater than 25% mixture of cells were reported as reliable detection limit by tube technique and this limit is largely driven by technological skill and experience.⁵

Table 1: Summary of patient blood group in different methods

| | Method | Anti A | Anti B | Anti D1 | Anti D2 | A1cells | B cells | O cells |
|-----------------------|-------------|--------|----------|---------|---------|---------|---------|---------|
| Patient Sample | SPRCA | 0 | 0 | 0 | 0 | 4+ | 0 | 0 |
| | Tube at RT | 0 | 0 | 0 | ND | 3+ | 0 | 0 |
| | Tube at 4°C | 0 | Weak/ Mf | Weak/Mf | ND | 3+ | 0 | 0 |
| | CAT | 0 | Mf | Mf | ND | 3+ | 0 | ND |
| Pre transplant Sample | SPRCA | 0 | 4+ | 4+ | 4+ | 4+ | 0 | 0 |

Conclusion

This case with the presence of separate group O/B, D+/- RBC population in grouping emphasize that chimerism due to ABO and Rh D incompatible transplantation is not uncommon any more. The mixed field agglutination reaction was missed with SPRCA while CAT clearly displayed the reaction pattern which helped in resolving the discrepancy early. For resolving grouping discrepancies, all discrepant blood groups should be performed with minimum of two different platforms. Most often the causes for mixed field reactions in ABO and Rh D grouping can be easily ascertained from patient clinical history. All blood samples with clinical history suspicion for blood group chimerism should be confirmed with CAT platform. Adequate training should be catered to the lab technicians to detect mixed field reactions in blood grouping. Resolving such discrepancies require proper clinical details especially recent transfusion or transplantation in the blood request form; which will prevent undue delay in issue of report or blood components.

References

1. Yang HS, Shin JG, Yang JJ, Choi JC, Park TS, Lee JY, Kim HR, Lee JN, Oh SH. ABO genotype-phenotype discrepancy due to chimerism resolved by clonal separation. *Ann Hematol.* 2017 Sep;96(9):1583-1585.
2. Van Dijk BA, Boomsma DI, De Man AJM. Blood Group Chimerism in Human Multiple Births Is Not Rare. *American Journal of Medical Genetics.* 1996;61:264-268.
3. Summers T Jr, Johnson VV, Stephan JP, Johnson GJ, Leonard G. The value of automated gel column agglutination technology in the identification of true inherited D blood types in massively transfused patients. *Transfusion.* 2009 Aug;49(8):1672-7.
4. Greendyke RM, Wormer JL, Banzhaf JC. Quality assurance in the blood bank: studies of technologist performance. *Am J Clin Pathol.* 1979;71:286-90.
5. Parker JL, Marcoux DA, Hafleigh EB, Grumet FC. Modified microtiter tray method for blood typing. *Transfusion.* 1978;18:417-22.