

6-1-2019

Sino-orbital fungal granuloma: A diagnostic dilemma

Henry Seow

Dept of ENT, Kasturba Medical College, Manipal, MAHE, rohit.singh@manipal.edu

Rohit Singh

Dept of ENT, Kasturba Medical College, Manipal, MAHE, rohit.singh@manipal.edu

Dipak Ranjan Nayak

Dept of ENT, Kasturba Medical College, Manipal, MAHE, dipak.nayak@manipal.edu

Manali Hazarika

Dept of Ophthalmology, Kasturba Medical College, Manipal, MAHE, manali.hazarika@manipal.edu

Follow this and additional works at: <https://impressions.manipal.edu/mjms>



Part of the [Medicine and Health Sciences Commons](#)

Recommended Citation

Seow, Henry; Singh, Rohit; Nayak, Dipak Ranjan; and Hazarika, Manali (2019) "Sino-orbital fungal granuloma: A diagnostic dilemma," *Manipal Journal of Medical Sciences*: Vol. 4 : Iss. 1 , Article 7. Available at: <https://impressions.manipal.edu/mjms/vol4/iss1/7>

This Case report is brought to you for free and open access by the MAHE Journals at Impressions@MAHE. It has been accepted for inclusion in Manipal Journal of Medical Sciences by an authorized editor of Impressions@MAHE. For more information, please contact impressions@manipal.edu.

Case Report

Sino-orbital fungal granuloma: A diagnostic dilemma

Henry Seow, Rohit Singh, Dipak Ranjan Nayak*, Manali Hazarika

Email: drnent@rediffmail.com

Abstract

Fungal granuloma of the sino-orbital region is uncommon. Although imaging modalities like CECT and MRI scans are usually helpful, a pre-operative diagnosis may still be difficult because of subtle overlapping clinical features and a rather indolent disease course. Due to the anatomical relations of the orbit, FNAC is generally difficult and has a high incidence of complications and false-negative results. We report a case of a middle-aged woman, who presented with a painless, progressive swelling below her right eyebrow with difficulty in looking upwards and to the right. Initial diagnoses of orbital dermoid cyst and frontal sinus mucocoele were made clinically. The origin of this lesion was unclear, was it a primary orbital pathology with secondary involvement of the frontal sinus, or vice versa? CECT and USG-guided FNAC aided in investigating, however, a definitive diagnosis of fungal granuloma was only established post-operatively, with the help of histopathological examination.

Key words: Aspergillus, granuloma, sino-orbital region

Introduction

The anatomical topography of the human orbit – surrounded by paranasal sinuses and the cranial cavity, enabling it for locoregional spread of disease processes in that zone – makes the orbit an “interdisciplinary” region.^{1,2,3} Various pathologies can also produce space-occupying lesions in and around the orbit.⁴ Albeit uncommon, fungal granuloma is one of them and has been mainly reported in India, Sudan, Pakistan and sometimes in the United States.⁵ The disease is most prevalent in villagers of tropical regions especially among those who are active in farm work. Following the inoculation of fungal organism, the initial site of involvement is usually the paranasal sinuses, with maxillary sinus being the most frequently affected (84.4 %), followed by the sphenoid sinus (14.4 %). Ethmoid and, especially, frontal sinus involvement is rare.⁶

Orbital involvement is usually secondary in cases of fungal granuloma. However, patients can present initially to the ophthalmologist with ocular complaints. We herein report a case of right sided sino-orbital fungal granuloma in a healthy adult.

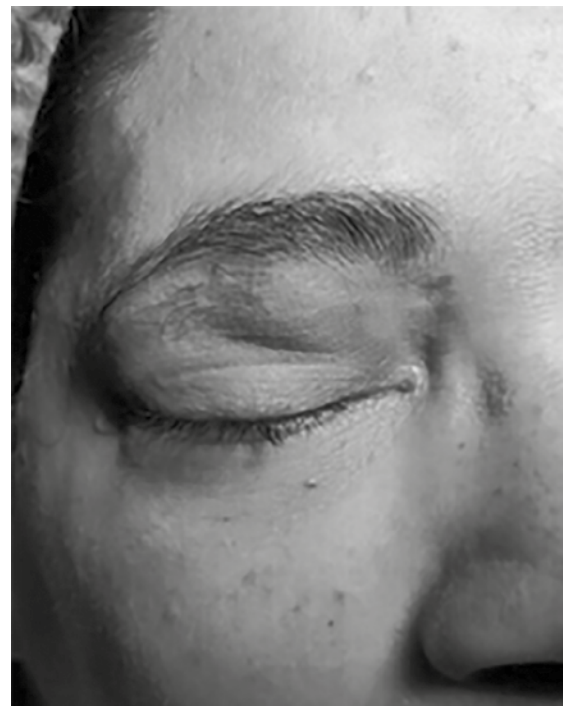

Figure 1: Showing the right supraorbital mass

Henry Seow¹, Rohit Singh¹, Dipak Ranjan Nayak^{1*},
Manali Hazarika²

Dept of ENT¹ and Ophthalmology²
Kasturba Medical College, Manipal, MAHE

*Corresponding Author

Manuscript received : 19/3/2018

Revision accepted : 14/9/18

How to cite this article: Seow H, Singh R, Nayak DR, Hazarika M. Sino-orbital fungal granuloma: A diagnostic dilemma. *MJMS*. 2019; 4(1): 33-37.

Case report

A 52-year-old female presented to the ophthalmology outpatient clinic in Kasturba Hospital Manipal, India, with a swelling just below her right eyebrow. It started insidiously three months ago and was gradually progressive in size. She had difficulty in looking upwards and to the right. However, it was painless and she had no complaints of disturbances to her vision. On examination, her extra-ocular movements showed restriction of right elevation and a firm 3x2cm solitary mass was noted in the right upper orbit (Figure 1).

The mass was mobile, non-tender and non-pulsatile. Cough impulse was negative and its superior margin cannot be felt separately. The right eyeball is found to be displaced downwards. Left eye is normal. Visual examination revealed 6/24 vision on both eyes. Exophthalmometry done showed right eye to be 20mm and left eye 18mm. CECT revealed a well-defined soft tissue density lesion measuring 2.0 x 1.8 x 1.8 cm, noted involving inferior portions of right frontal sinus, preseptal space and extraconal space of right orbit. Expansion of the partially opacified right frontal sinus was also noted with smooth scalloping of its related bony boundaries showing erosion and dehiscence of its inferior wall and subsequent encroachment on the right orbital cavity by bulging soft tissue with mild adjacent fat stranding which is seen mildly displacing the right globe downwards (Figure 2a, b).

Differential diagnoses of orbital dermoid cyst and frontal sinus mucocele were initially made as the patient had no significant sino-nasal complaints. However, she was then referred to the ENT department for further management. USG-guided FNAC was done under strict aseptic precaution and it revealed occasional cyst macrophages in a proteinaceous background without any malignant cells.

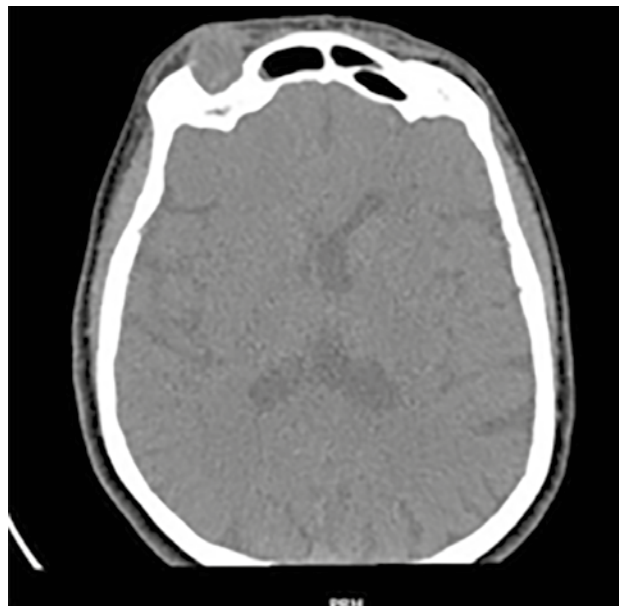

Figure 2a: Axial CT image showing soft tissue lesion involving extraconal space of right orbit

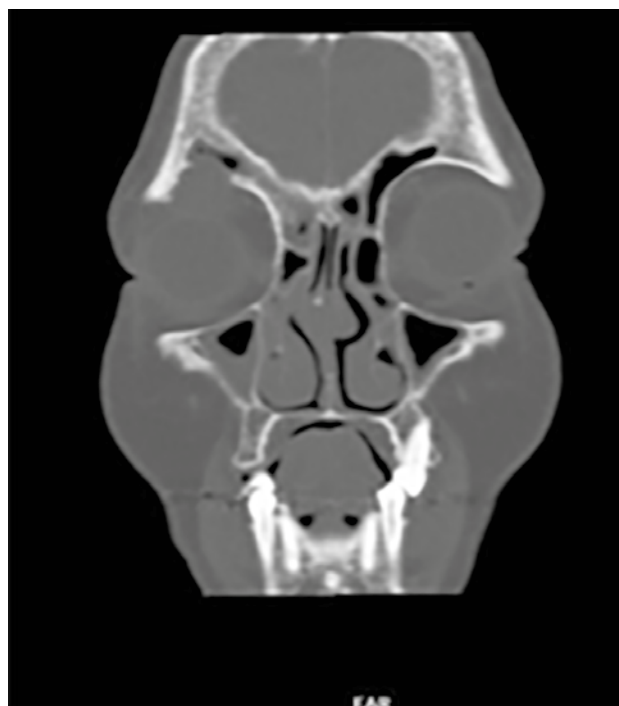

Figure 2b: Coronal CT image showing lesion in right orbit with frontal sinusitis and erosion of its inferior wall

Diagnostic Nasal Endoscopy (DNE) showed mucoid discharge in nasal cavity. Routine blood investigations were normal. Surgical excision of the swelling with reconstruction of floor of frontal sinus with cartilage allograft was planned. A curvilinear incision was made along the lower margin of right eyebrow. The muscles were divided and orbital fat

was identified. Intraoperatively a cystic swelling was present in the supraorbital region with a breach in the floor of frontal sinus (Figure 3). During dissection the swelling ruptured to reveal cheesy material within it and its wall was attached to the floor of the frontal sinus with erosion of bone (Figure 4). The cyst was removed in-toto along with its wall and sent for histopathological examination (HPE). Reconstruction of the defect on the floor of the frontal sinus by septal cartilaginous allograft was done and closed in 2 layers of muscles with 3-0 Vicryl. Skin incision was closed. Post-operative follow-up was done one week later and the patient was asymptomatic and the incision wound had healed well. HPE report revealed features suggestive of a fungal granuloma – *Aspergillus*. She was then started on Itraconazole 100mg tablets twice daily for one month and continued to be asymptomatic on last follow up. Normal saline douches and fluticasone furoate nasal spray were advised for 1 month in view of sinusitis.

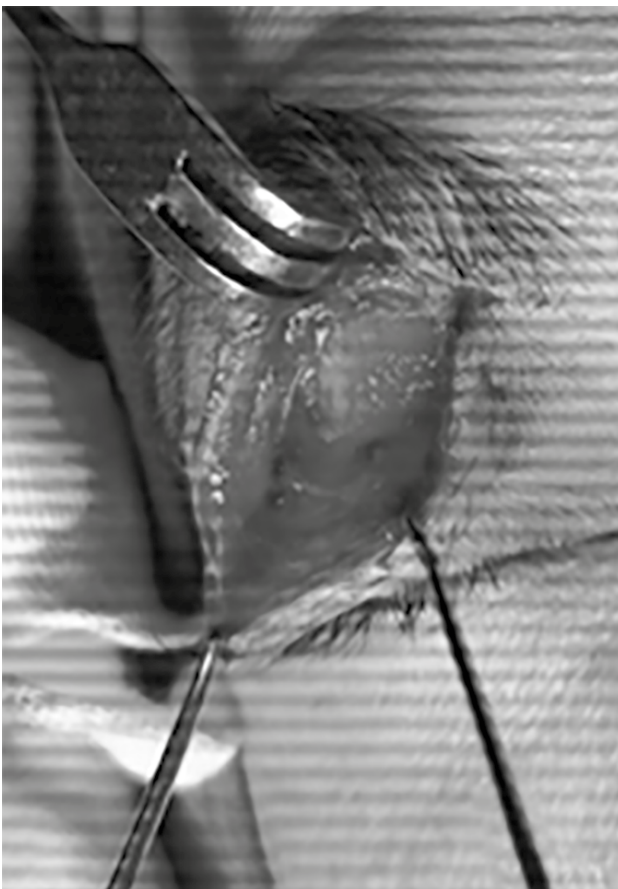


Figure 3: Operative dissection and exposing the mass lesion

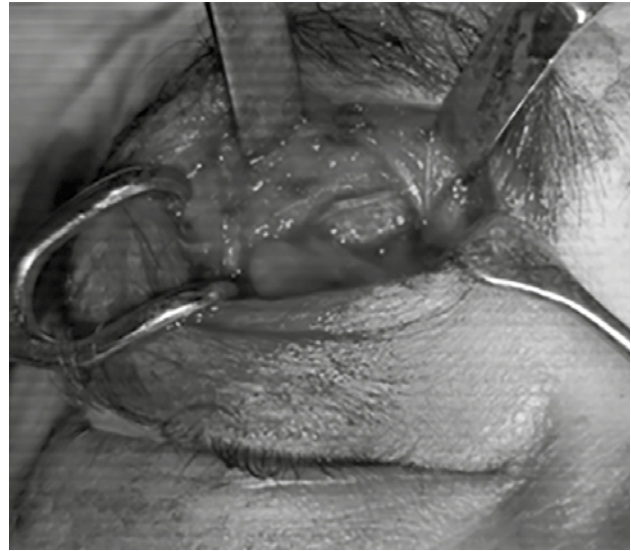


Figure 4: Erosion of the bony floor of frontal sinus

Discussion

Fungal granuloma is a locally aggressive focal expanding granulomatous mass, resulting from sequestration of densely tangled, concentrically arranged masses of fungal hyphal elements, associated with invasion and destruction of adjacent structures.⁶ The disease has an insidious onset and takes a chronic gradual course over several months and occasionally years. It commonly affects immunocompetent patients. Most orbital fungal infections are aspergillosis and mucormycosis. *Aspergillus flavus* is the organism most frequently isolated.⁷ The disease often presents late, at advanced stages, due to the paucity of symptoms in the initial period. Clinical presentation is mainly due to the mass effect, commonly with nasal complaints especially nasal obstruction, also possibly proptosis or rarely even cranial nerve palsies.

In our patient, the initial diagnostic dilemma was in making a diagnosis for the sino-orbital mass. The patient's clinical presentation made us propose an initial diagnosis of orbital dermoid cyst, with frontal sinus mucocoele being the next differential diagnosis. Orbital pseudotumor is also a differential for an orbital mass, especially in the setting of chronic infection or immunosuppression hence was ruled out.⁸ Neoplastic conditions have also been kept in mind.

Dermoid cysts are benign cystic lesions that arise from congenital cell rests. Most orbital dermoid cysts are located anteriorly, especially on the fronto-zygomatic suture line. Growth of the mass results from slow production and subsequent accumulation of dermal products within the cyst. Patients are usually asymptomatic with primarily cosmetic concerns due to the superficial locations of these masses. On CT imaging, these lesions are well-delineated, have smooth margins and may have a fluid level.⁹ Surgical excision is the treatment of choice.

Mucoceles of the paranasal sinuses are epithelium-lined cystic masses usually occurring as a result of sinus ostia obstruction. Frontal and ethmoid sinuses are most common sites. While ophthalmologic symptoms are most frequent, rhinological and neurological complaints may also be reported by the patients. CT imaging displays a non-enhancing homogenous mass with scalloped margin associated with expansion of bony walls. The standard treatment is surgical excision with trends towards endoscopic techniques.¹⁰

The above differential diagnoses were ruled out based on the final histopathological report which was suggestive of a fungal granuloma with etiology suggestive of *Aspergillus*, hence highlighting the importance of excision biopsy in such cases.

The dilemma of the origin of the disease, whether it was arising from the frontal sinus or the anterior orbit, was also a rather challenging one. Clinical history obtained did not provide any clue for resolving this dilemma. CECT scan findings were also non-specific as mentioned above. However, intraoperatively we have noted a breach in the floor of frontal sinus with the mass encroaching into the orbital space from above. Hence it was suggestive that the sino-orbital mass was more likely to be secondary to fungal sinusitis, with extension of the disease into the orbital space.

There is scarce evidence regarding optimal management of this condition in the literature.

However, initial conservative surgical excision of the mass is generally indicated, followed by medical treatment with antifungal agents (itraconazole/voriconazole).¹¹ Prognosis is generally good, especially if there is no intracranial invasion. Relapse of the disease is not uncommon, especially if antifungal therapy is not appropriately established in the post-operative period.

References

1. Schwartz RM, Coupland SE, Finger PT. Cancer of the orbit and adnexa. *Am J Clin Oncol.* 2013;36(2):197–205.
2. Chipczyńska B, Grałek M, Hautz W, et al. Orbital tumor as an initial manifestation of Wegener's granulomatosis in children: a series of four cases. *Med Sci Monit.* 2009;15(8):CS135–38.
3. Gerbino G, Boffano P, Benech R, et al. Orbital lymphomas: Clinical and radiological features. *J Craniomaxillofac Surg.* 2013 pii: S1010-5182(13)00215-1.
4. Sarah N. Khan, Ali R. Sepahdari. Orbital masses: CT and MRI of common vascular lesions, benign tumors, and malignancies. *Saudi J Ophthalmol.* 2012 Oct; 26(4): 373–383.
5. Stringer SP, Ryan MW. Chronic invasive fungal rhinosinusitis. *Otolaryngol Clin North Am* 33:375–387, 2000.
6. Nathan A. Deckard, Bradley F. Marple, and Pete S. Batra. *The Role of Fungus in Diseases of the Frontal Sinus.* The Frontal Sinus. 2nd ed. Springer; 2016; 156.
7. Mukherjee B, Raichura ND, Alam MS. Fungal infections of the orbit. *Indian J Ophthalmol* 2016;64:337-45
8. Mitchell R. Gore. Orbital pseudotumor as a result of chronic sinusitis in an **HIV-positive patient** *Clin Case Rep.* 2017 Nov; 5(11): 1793–1796.
9. Tim E. Darsaut, Giuseppe Lanzino, M. Beatriz Lopes, Steven Newman. An introductory overview of orbital tumors. *Neurosurg Focus* 10 (5):Article 1, 2001

10. Gregory G. Capra, Peter N. Carbone, David P. Mullin. Paranasal Sinus Mucocele. *Head Neck Pathol.* 2012 Sep; 6(3): 369–372. extending into the pterygopalatine fossa and orbital floor: A case report. *Med Mycol Case Rep.* 2012;1(1):107-11.
11. Kim TH, Jang HU, Jung YY, Kim JS. Granulomatous invasive fungal rhinosinusitis