

SPIGELIAN HERNIA – UNVEILING A RARE CASE REPORT



Samyuktha Santhosh, SSIMS&RC

Dr L.S Patil HOD Department of General Surgery

INTRODUCTION

- Spigelian hernia is a ventral hernia observed to be protruding out of the spigelian aponeurosis.
- Spigelian aponeurosis is the aponeurosis of the transverse abdominis muscle limited laterally by Linea semilunaris and medially by lateral border of rectus abdominis.
- Spigelian hernia is a rare entity constituting 0.12% of abdominal wall hernias.

DISCUSSION

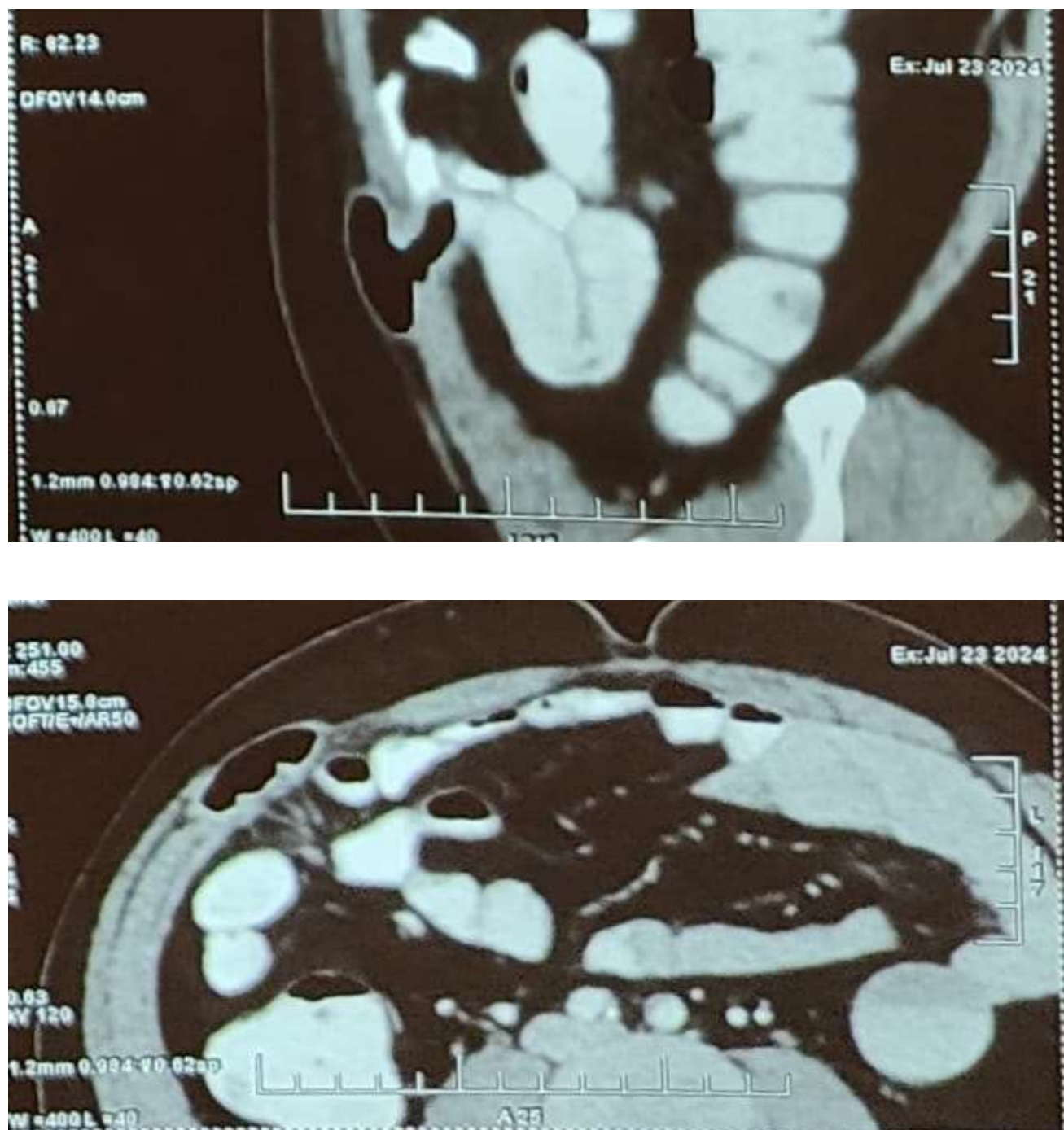
Patient has a classical presentation of a rare disease including complaints of swelling and pain abdomen without symptoms of intestinal obstruction.

The possible risk factors in this particular case includes -

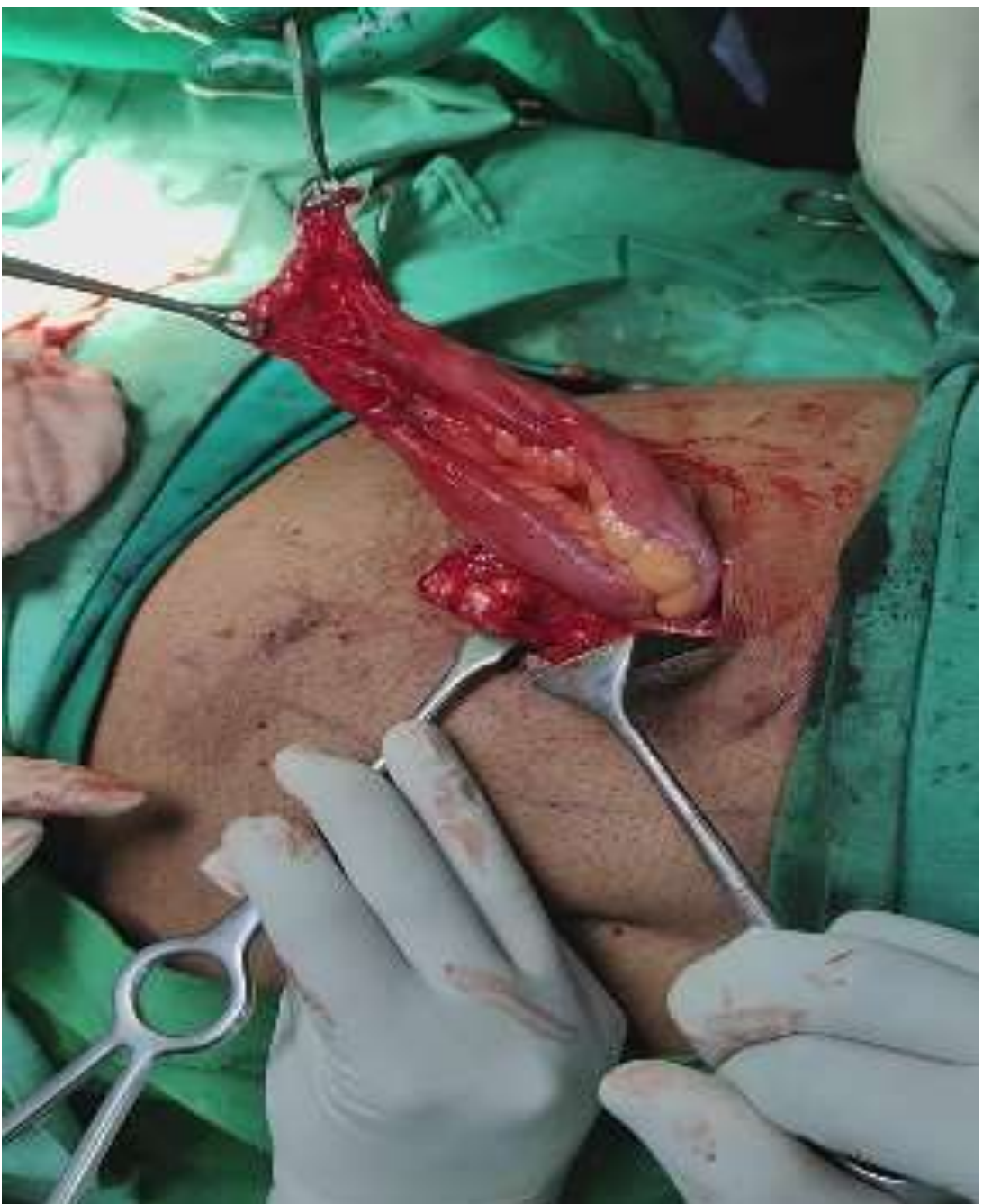- History of lifting heavy weights
- Past history of robotic pyeloplasty 1 year ago.
- History of smoking for the past 10 years.

CONCLUSION

The occurrence of Spigelian hernia in this case is probably linked to the laparoscopic placement of lateral ports in robotic pyeloplasty. Closure of the lateral port sites surgically might alter the incidence of this type of hernia.



CECT Abdomen showing right sided ventral hernia containing bowel loops



Intraoperative picture of hernial sac

CASE

History

- A 59 year old man who is a farmer by occupation presented with complaints of – Swelling in the right flank since 2 months, pain abdomen since 2 months
- He has a history of robotic pyeloplasty one year ago and is a known case of chronic bronchitis
- He is a smoker since 10 years

Examination

Abdominal examination revealed a transversely ovoid swelling of size 6.5 * 7 cm in the right lumbar region with expansile cough impulse and positive reducibility

Investigations

- CECT Abdomen – showing right sided ventral hernia containing bowel loops
- USG abdomen

MANAGEMENT

Hernioplasty with Lichenstein’s tension free mesh repair was performed.

1. Skandalakis PN et al. Spigelian hernia: surgical anatomy, embryology, and technique of repair. Am Surg. 2006 Jan.

2. Mittal T et al. Diagnosis and management of Spigelian hernia: A review of literature and our experience. J Minim Access Surg. 2008 Oct.

3. Giri Goswami A et al. Spigelian Hernia: Clinical Features and Management [Internet]. Hernia Surgery. IntechOpen. 2022.

4. Morrison CP, Wemyss-Holden SA, Iswariah H, Maddern GJ. Lateral laparoscopic port sites should all be closed: the incisional "spigelian" hernia. Surg Endosc. 2002 Sep