

7-1-2016

## Little old lady's hernia" – A report of a rare case

Anil Raj A Mr

*Manipal College of Nursing*, anilrajan1987@gmail.com

Benakatti Rajendra Dr

*KMC, Manipal*, dr.rajendra.benakatti@gmail.com

Follow this and additional works at: <https://impressions.manipal.edu/mjnhs>



Part of the [Nursing Commons](#)

---

### Recommended Citation

A, Anil Raj Mr and Rajendra, Benakatti Dr (2016) "Little old lady's hernia" – A report of a rare case," *Manipal Journal of Nursing and Health Sciences*: Vol. 2: Iss. 2, .

Available at: <https://impressions.manipal.edu/mjnhs/vol2/iss2/18>

This Case Report is brought to you for free and open access by the MAHE Journals at Impressions@MAHE. It has been accepted for inclusion in Manipal Journal of Nursing and Health Sciences by an authorized editor of Impressions@MAHE. For more information, please contact [impressions@manipal.edu](mailto:impressions@manipal.edu).

## “Little old lady’s hernia” – A report of a rare case

Anil Raj A, Benakatti Rajendra\*

Email: dr.rajendra.benakatti@gmail.com

### Abstract

‘Little old lady’s hernia’ is another name for Obturator hernia, which is the rarest form of Pelvic Hernias’. A 78 year old thin woman was admitted with five days history of pain abdomen and abdominal distension. It was associated with constipation and post meal non-bilious vomiting. With the help of abdominal Computer tomography (CT), it was diagnosed as Obturator hernia. Exploratory laparotomy was done to reduce Hernia. Post-operative period was uneventful; she was thermodynamically stable and was discharged on the fifth post-operative day.

**Keywords:** Little old lady’s hernia, Obturator hernia, CT abdomen, exploratory laparotomy

### Introduction

‘Little old lady’s hernia’ is another name for Obturator hernia, which is the rarest form of Pelvic Hernias. In 1724, Obturator hernia was initially identified and defined by Arnaud de Ronsil and in 1851 Obre did the first effective reduction of Obturator hernia (Igari et al., 2010). This is usually seen among multiparous lean elderly women. Chronic obstructive pulmonary disease, frequent constipation, ascites, and kyphoscoliosis are the major risk factors of the disease (Blach & Ghosh, 2014).

### Case report

A 78 year old thin woman (Height 153cm, weight 41kg), with known hypertensive and asthmatic was admitted with a five-day history of colicky pain in the abdomen and distended abdomen. It was associated with constipation and post meal non-bilious vomiting. Abdominal pain reduced in its severity after vomiting. On clinical examination, she had blood pressure of 148/98 mm of Hg, body temperature of 98.8 °F, pulse of 86/minute, and respiratory rate of 22/minute. Local examination showed abdominal distension (++) with

diffuse tenderness, visible peristalsis and normal bowel sounds. Other examination findings were no palpable mass, no palpable organomegaly and no free fluid in the abdominal region. Laboratory results revealed normal blood profile. X-ray abdomen (Fig. 1) showed features suggestive of intestinal obstruction and CT abdomen (Fig. 2 and 3) revealed a right obstructed obturator hernia.

Pre-operatively she was kept on Nil per orally (NPO), continuous ryles tube aspiration, IV fluid therapy and broad spectrum antibiotic (Cefoperazone+Sulbactam 1.gm I.V. TID). She underwent emergency exploratory laparotomy under general anaesthesia. Defect in obturator canal (6x5cm) was repaired with non-absorbable sutures, the gangrenous ileal segment (about 20cm in fig. 4) was removed and end-to-end anastomosis was done.

She was kept in post-operative ICU for one day with broad-spectrum antibiotic (Cefoperazone + Sulbactam 1.5gm I.V. TID), adequate nutritional support and careful monitoring of the vital organs. Her post-operative period was uneventful. Feeding was resumed once the bowel begun to function. She was hemodynamically stable and was discharged on the fifth day, post-operative.

Nursing management for her post-operative period was focused on pain management, early ambulation,

#### Anil Raj A

Administrative Officer, ICMR-DHR Funded Geriatric Project, Manipal College of Nursing Manipal

#### Benakatti Rajendra

Assistant Professor, Department of Surgery, KMC, Manipal

\* Corresponding Author

**How to cite this article:** Raj, A. A., & Rajendra, B. (2016). Little Old Lady’s Hernia- Report of a rare case. *Manipal Journal of Nursing and Health Sciences*, 2(2), 69-71.

post-operative nutritional therapy, infection control, chest physiotherapy and wound care.

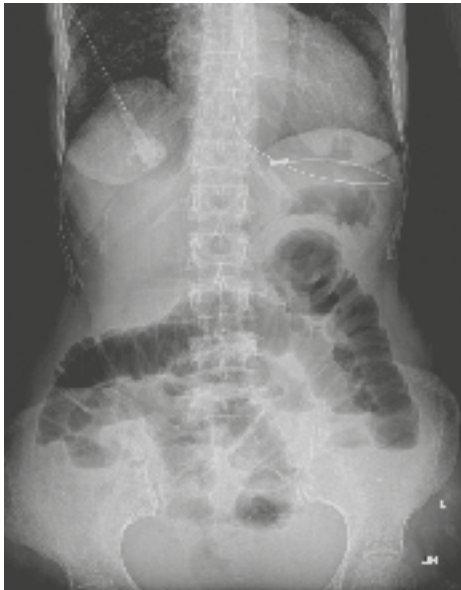

Figure 1. X-ray Abdomen Showing Intestinal Obstruction

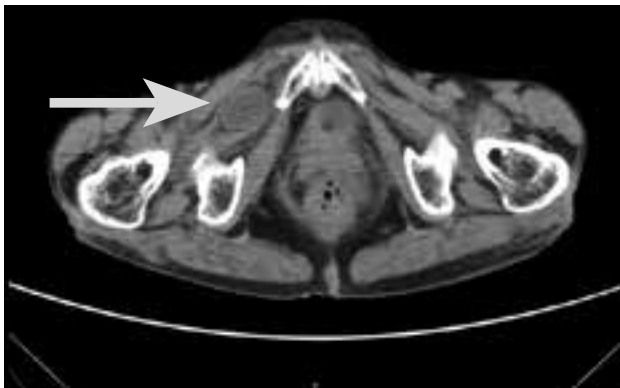


Figure 2. CT Abdomen Showing Obstructed Obturator Hernia

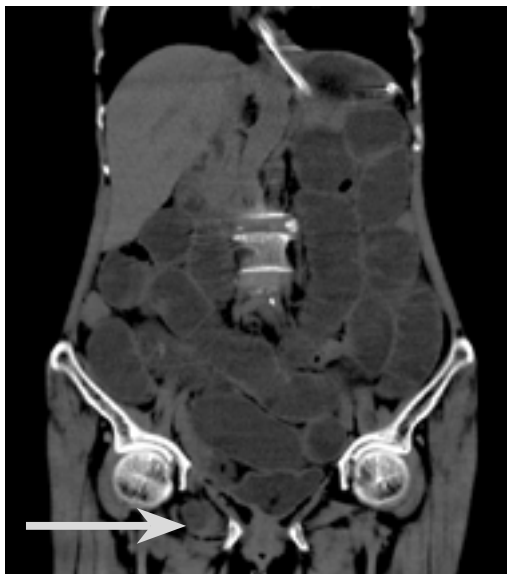


Figure 3. CT Abdomen Showing Obstructed Obturator Hernia

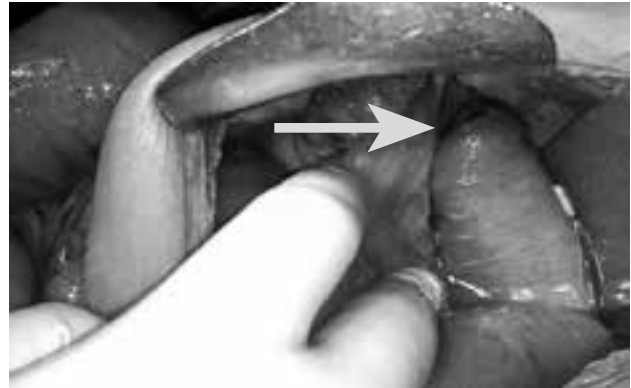


Figure 4. Intra Operative Picture of Obstructed Obturator Hernia

### Discussion

On either side, in the anterolateral pelvic wall inferior to the acetabulum obturator foramen is situated and obturator hernia proceeds through it (Shukla, Bharti, Rattan, Chaudhary, & Chaudhary, 2015). Fat and extra peritoneal connective tissue gives protection to the obturator nerves and blood vessels, which passes through this channel. As age advances and with loss of weight, an increase in the possibility of obturator hernia is observed (Nasir et al., 2012). Since women have broader pelvis and, bigger and more triangular obturator foramen, they are affected approximately six times more frequently when compared to men (Tokushima et al., 2014). As sigmoid colon overlies the left obturator channel, the hernia is more commonly presents on the right side, with a ratio of 3:1 and bilateral hernias are uncommon (Hennekinne-Mucci et al., 2003). It is more commonly seen among Asian population when compared to rest of the world. When all abdominal wall hernias are considered, the incidence of obturator hernia is approximately less than one percentage (Karasaki, Nakagawa, & Tanaka, 2014).

Patients with acute intestinal obstruction, usually complain of persistent attacks of constipation (Rajendran, Murphy, & O'Hanlon, 2009). As the signs and symptoms are vague, timely diagnosis is very essential. Ultrasonography and CT scan are the important imaging measures helpful to establish the diagnosis. Among them, CT scan has better sensitivity, specificity and accuracy (Mantoo, Mak, & Tan, 2009).

Surgery is the only management option for obturator hernia. There are various surgical approaches such as inguinal, retropubic, and transperitoneal approach (Kisaoglu, Ozogul, Yuce, Bayramoglu, & Atamanalp,

2014). In case of emergency, the abdominal approach via a low midline incision is most frequently preferred, as it allows reasonable visualization of the obturator foramen as well as the proper detection and resection of any ischaemic bowel (Tee, Evans, Ratnayake, & Strekozov, 2014). Nursing management of these patients should focus on managing the paralytical ileus, pain management and early ambulation to prevent the further surgical complications for the patients (Wang, Ho, & Wei, 2006)

## Conclusion

Obturator hernia is a significant cause of intestinal obstruction although very rare, especially between a thin elderly woman and a diagnostic challenge. CT scan is an important diagnostic tool to establish pre-operative diagnosis. The need for the awareness of an early diagnosis is stressed with an emphasis on surgical management.

Sources of support: None

Conflict of interest: None declared

Source of support in form of grants: None

Ethical approval: Written informed consent was obtained from the patient for publication of this case report and the images.

## References

- Blach, O., & Ghosh, A. (2014). "Little old lady's hernia" causing small bowel obstruction in a man: a case report with a review of literature on the pathophysiology of obturator hernias. *BMJ Case Reports*, 2014, 1-2. doi.org/10.1136/bcr-2014-206574
- Hennekinne-Mucci, S., Pessaux, P., Du Plessis, R., Regenet, N., Lermite, E., & Arnaud, J. (2003). Hernie obturatrice étranglée : à propos de 17 cas. *Annales de Chirurgie*, 128(3), 159–162. doi.org/10.1016/S0003-3944(03)00052-X
- Igari, K., Ochiai, T., Aihara, A., Kumagai, Y., Iida, M., & Yamazaki, S. (2010). Clinical presentation of obturator hernia and review of the literature. *Hernia*, 14(4), 409–413. doi.org/10.1007/s10029-010-0658-z
- Karasaki, T., Nakagawa, T., & Tanaka, N. (2014). Obturator hernia: The relationship between anatomical classification and the Howship-Romberg sign. *Hernia*, 18(3), 413–416. doi.org/10.1007/s10029-013-1068-9
- Kisaoglu, A., Ozogul, B., Yuce, I., Bayramoglu, A., & Atamanalp, S. S. (2014). Obturator Hernia, a Rare Cause of Small Bowel Obstruction: Case Report. *The Eurasian Journal of Medicine*, 46(3), 224–226. doi.org/10.5152/eajm.2014.56
- Mantoo, S. K., Mak, K., & Tan, T. J. (2009). Obturator hernia: Diagnosis and treatment in the modern era. *Singapore Medical Journal*, 50(9), 866–870.
- Nasir, B. S., Zendejas, B., Ali, S. M., Groenewald, C. B., Heller, S. F., & Farley, D. R. (2012). Obturator hernia: The Mayo Clinic experience. *Hernia*, 16(3), 315–319. doi.org/10.1007/s10029-011-0895-9
- Rajendran, S., Murphy, M., & O'Hanlon, D. (2009). Little old ladies' hernia: a clinical diagnostic conundrum. *BMJ Case Reports*, 2009. published online 21 June 2009. doi.org/10.1136/bcr.01.2009.1470
- Shukla, A., Bharti, R., Rattan, A., Chaudhary, R., & Chaudhary, U. (2015). Little old lady's hernia; a surgeons challenge. *International Journal of Surgery and Medicine*, 147-148. doi.org/10.5455/ijsm.20150820122221
- Tee, C. L., Evans, T., Ratnayake, S., & Strekozov, B. (2014). Small bowel obstruction secondary to bilateral obturator hernia: a rare occurrence. *Journal of Surgical Case Reports*, 2014(2) 1-3. doi.org/10.1093/jscr/rju009
- Tokushima, M., Aihara, H., Tago, M., Tomonaga, M., Sakanishi, Y., Yoshioka, T., ... Yamashita, S. I. (2014). Obturator hernia: A diagnostic challenge. *American Journal of Case Reports*, 15, 280–283. doi.org/10.12659/AJCR.890555
- Wang, S. L., Ho, K. C., & Wei, C. Y. (2006). Laparoscopic repair of obturator hernia. *Surgical Practice*, 167–170. doi.org: 10.4293/CRSLS.2014.00168